

Takehiko Yamaguchi
Howard D. Dorfman
Sidney Eising

Cherubism: clinicopathologic features

Received: 30 November 1998
Revision requested: 5 January 1999
Revision received: 16 February 1999
Accepted: 19 February 1999

This case report was presented at the 25th Closed Meeting of the International Skeletal Society in Dublin, September 1998

T. Yamaguchi, M.D.
H.D. Dorfman, M.D. (✉)
Section of Orthopaedic Pathology,
Department of Orthopaedic Surgery,
Montefiore Medical Center/
Albert Einstein College of Medicine,
111 East 210th Street, Bronx, NY
10467–2490, USA

T. Yamaguchi, M.D.
Department of Pathology,
Dokkyo University School of Medicine,
Mibu, Tochigi 321–0293, Japan

S. Eising, D.D.S.
Department of Oral Surgery,
Montefiore Medical Center/
Albert Einstein College of Medicine,
Bronx, New York, USA

Introduction

Cherubism, which was first described as familial multilocular cystic disease of the jaws by Jones [1] in 1933, is characterized by symmetrically swollen cheeks, particularly over the angles of the mandible, and upward turning of the eyes, which imparts a cherubic appearance. The affected mandible, and sometimes the maxilla, begin to swell in early childhood and this gradually increases until pu-

Abstract A case of cherubism in 6-year-old boy is reported. He presented with bilateral symmetrical enlargement of the jaw in addition to medially dislocated premature teeth, narrow V-shaped palatal vault, and mild upward turning of the eyes. Radiographs showed multiloculated osteolysis in both the mandible and maxilla. Histology revealed a non-neoplastic fibrous lesion, rich in multinucleated giant cells, consistent with giant-cell reparative granuloma. Since the original description of cherubism, various histologic interpretations have been proposed, particularly that of fibrous dysplasia. However, it should be emphasized that cherubism is a disease histologically indistinguishable from giant-cell reparative granuloma.

erty [2–4]. Although the condition is known to regress spontaneously at puberty, surgical management is sometimes required for cosmetic reasons [3, 5]. The microscopic features of the lesion reveal a non-neoplastic fibrous lesion, rich in multinucleated giant-cells, which cannot be distinguished from giant-cell reparative granuloma or brown tumor of hyperparathyroidism [2–4]. Since its original description, various histologic interpretations for this condition have

Key words Cherubism · Familial multilocular cystic disease of the jaws · Giant-cell reparative granuloma · Fibrous dysplasia

been proposed, including fibrous dysplasia, giant cell tumor, and giant-cell reparative granuloma [6–11].

We present a non-hereditary case of cherubism with a review of the literature, and discuss the histologic characteristics of this condition.

Case report

A 6-year-old Hispanic boy, who was the product of a normal pregnancy

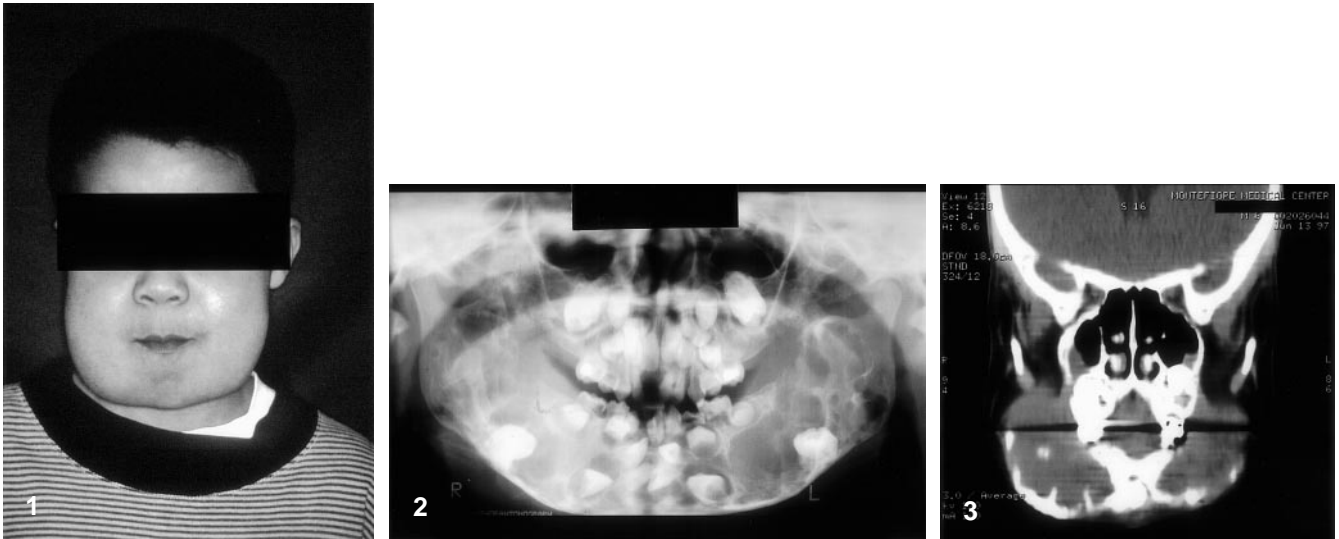


Fig. 1 Patient's face showing symmetrical swelling of the cheeks and mandibular angles (the right side is somewhat more prominent than the left)

Fig. 2 Panoramic radiograph of the jaw shows multilocular osteolytic lesions, bilaterally in the mandible, with centrally dislocated teeth

Fig. 3 CT scan reveals marked expansion of the mandible which is filled with soft tissue-density tissue and thinned, disrupted cortex

and delivery, had been noted to have "puffy gums" since the age of 8 months. He was initially seen by an oral-maxillofacial surgeon at the age of 2 years. He was referred to our hospital in June 1997, because of increasing bilateral buccal swelling. The mandible and maxilla were expanded bilaterally, but no tenderness was noted. The patient underwent an operative procedure in the right part of the mandible for reduction of the cosmetic deformity in August 1997. His family history did not include any evidence suggestive of hereditary disease.

Physical examination revealed symmetrical enlargement of jaws with medially dislocated premature teeth, narrow V-shaped palatal vault, and mild upward turning of eyes (Fig. 1). No lymphadenopathy was noted. All available laboratory data were within normal limits.

A panoramic radiograph of the mandible revealed multiloculated osteolysis involving the entire mandible, with dislocated teeth (Fig. 2). CT scans showed soft tissue-intensity masses occupying the mandible and maxilla with disrupted cortex (Fig. 3). Three-dimensional CT scans exhibited a symmetrically expanded mandible with extensive osteolysis and bone destruction of both edges of the maxilla (*not shown*).

Microscopic examinations revealed hypervascular fibroblastic proliferation with unevenly distributed multinucleated giant cells of osteoclast type (Fig. 4). The proliferating fibroblasts showed bland nuclei, partly arranged in storiform pattern. Paucicellular areas with abundant collagen deposition and no multinucleated giant cells intermingled with cellular areas with a sharp demarcation (Fig. 5). There were some foci of hemorrhage usually associated with an abundance of multinucleated giant cells and hemosiderin deposition (Fig. 6). Mild chronic inflammatory infiltration was seen. No osteoid, bone, or chondroid formation was evident in the lesion. On the basis of these features, the diagnosis of giant-cell reparative granuloma was made.

At the 1-year follow-up there was significant improvement in the contour of the operated side. A pan-

oramic radiograph revealed increased density at the operative site.

Discussion

Cherubism is an autosomal dominant disorder. Hereditary (familial) and non-hereditary (non-familial) forms exist [2]. In 1938, it was introduced as a familial multilocular cystic disease of the jaw, a distinct entity they designated "cherubism" [1, 12]. Although the histologic features of the condition are usually interpreted as a giant-cell reparative granuloma, it is still occasionally described in the literature as fibrous dysplasia [13, 14].

The original and second articles on cherubism by Jones [1, 12] did not have any histologic descriptions of the disease. In 1950, Jones first described the microscopic features, showing a cellular fibrous lesion with multinucleated giant cells of osteoclastic type, in addition to numerous capillaries and several small hemorrhages with scattered deposits of granular hemosiderin. This was interpreted as fibrous dysplasia with a shift toward osteoclasts [6]. However, he did not mention any dysplastic bone formation without osteoblastic rimming, which is characteristic for fibrous dysplasia. In 1951, Caffey and Williams [7] reported five cases of the disease and

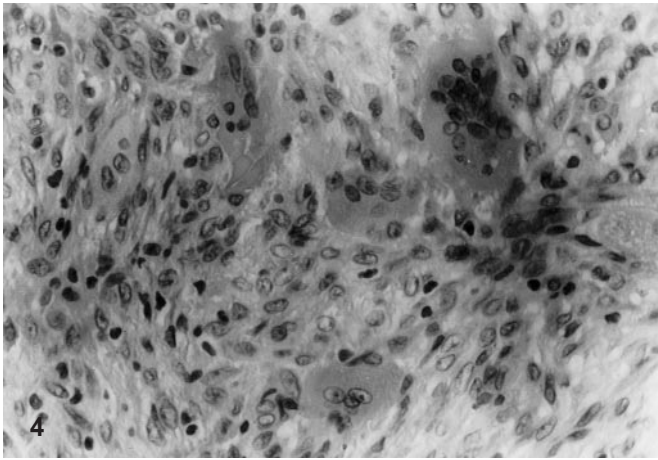


Fig. 4 High-power photomicrograph shows a benign fibroblastic proliferation with scattered multinucleated giant cells of osteoclast type (H&E, ×400)

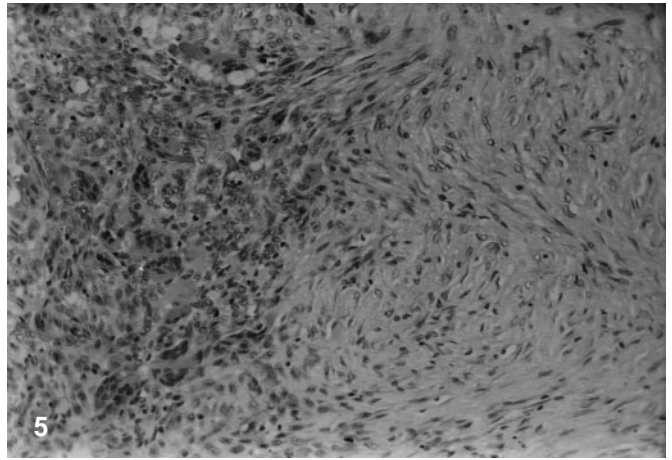


Fig. 5 Medium-power view reveals a clear demarcation of cellular area rich in multinucleated giant cells (*left*) and paucicellular fibroblastic proliferation arranged in storiform pattern (*right*) (H&E, ×200)

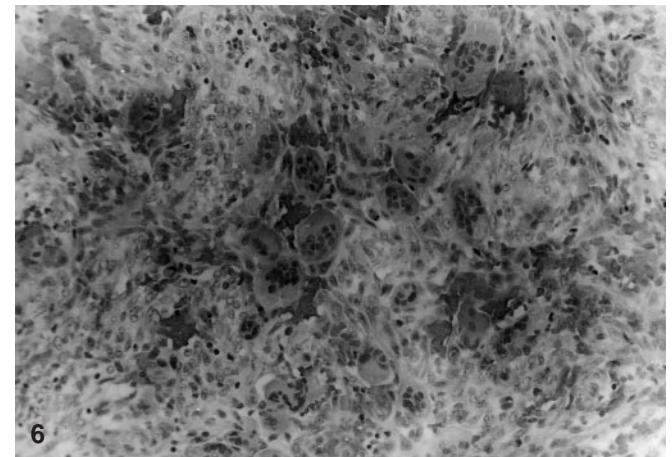


Fig. 6 Medium-power view shows an aggregation of multinucleated giant cells within an area of hemorrhage (H&E, ×200)

presented a histologic description in one of them. The main part of the lesion consisted of fibroblastic proliferation with scattered multinucleated giant cells. There was no evidence of cartilage or osteoid. However, they also interpreted this condition as fibrous dysplasia. In the same year, Waldron [8] documented three cases under the title of bilateral giant cell tumors of the jaw that were compatible with cherubism. The microscopic pictures in their articles retrospectively seem more likely to be a giant-cell reparative granuloma. At that time, the concept of giant-cell reparative granuloma had not yet been proposed. Jaffe [15] first introduced the concept of giant-cell reparative granuloma of the jaws in 1953. Bruce et al. [10] reported four cases of cherubism under the name of familial intraosseous fibrous swelling of the jaws in 1953. They sent one of

their cases in consultation to Jaffe, who opined that the histologic features were not compatible with fibrous dysplasia. In 1957, Seward and Hankey [11] reported four new cases of cherubism and considered the histologic features to be more compatible with giant-cell reparative granuloma than with fibrous dysplasia. In 1962, Thoma [16] stated that the microscopic features of cherubism were consistent with giant-cell reparative granuloma. In 1965, Jones [17] accepted Thoma's identification of the lesions of cherubism as giant-cell reparative granuloma.

In the present case, the microscopic features were compatible with giant-cell reparative granuloma, a non-neoplastic fibrous lesion with scattered multinucleated giant cells and foci of hemorrhage. No dysplastic bone trabeculae without osteoblastic rimming suggestive of fi-

brous dysplasia were seen in the lesion. Batsakis [2] stated that the lesions of cherubism had a looser, less cellular, delicate fibrous tissue component and did not contain the new bone formation characteristic of giant-cell reparative granuloma. Indeed, the present case showed looser areas, which were clearly adjacent to cellular areas with histologic features, well within the histologic spectrum of giant-cell reparative granuloma.

Even after Seward and Hankey [11] pointed out that the histologic features were more likely giant-cell reparative granuloma, case reports of cherubism have continued to appear with the designation of fibrous dysplasia [13, 14].

The diagnosis of cherubism is based on its clinical manifestations, but it has characteristic histologic features. Fibrous dysplasia of the

jaws can present with similar radiographic features to cherubism [18, 19]; however, it does not usually show the swollen cheeks or upward turning of eyes characteristic of cherubism. In addition, cherubism has the following characteristic features, which would be unusual for fibrous dysplasia: (1) symmetrical involvement, (2) limitation to the jaws, and (3) involution at puberty. Giant-cell reparative granuloma and fibrous dysplasia are pathogenetically different conditions. It should be emphasized that cherubism is a disease histologically indistinguishable from giant-cell reparative granuloma and should no longer be linked with fibrous dysplasia.

Despite their histologic similarity, giant-cell reparative granuloma in cherubism can be distinguished from conventional giant-cell reparative granuloma of the mandible by the radiographic presence of extensive bilateral mandibular involvement and the characteristic clinical features.

References

1. Jones WA. Familial multilocular cysts of the jaws. *Am J Cancer* 1933; 17:946–950.
2. Batsakis JG. Tumors of the head and neck: clinical and pathological considerations, 2nd edn. Baltimore London: Williams & Wilkins, 1979.
3. Kaugars GE, Niamtu III J, Svirsky JA. Cherubism: diagnosis, treatment, and comparison with central giant cell granulomas and giant cell tumors. *Oral Surg Oral Med Oral Pathol* 1992; 73:369–374.
4. Rosai J. Ackerman's surgical pathology, 8th edn. St Louis Baltimore Boston: Mosby, 1996.
5. Hamner III JE, Ketcham A. Cherubism: an analysis of treatment. *Cancer* 1969; 23:1133–1143.
6. Jones WA, Gerrie J, Pritchard J. Cherubism: a familial fibrous dysplasia of the jaws. *J Bone Joint Surg Br* 1950; 32:334–347.
7. Caffey J, Williams JL. Familial fibrous swelling of the jaws. *Radiology* 1951; 56:1–14.
8. Waldron CA. Familial incidence of bilateral giant cell tumors of the jaw. *Oral Surg Oral Med Oral Pathol* 1951; 4:198–207.
9. Riley P, Stuteville O, Brown RC. Familial fibrous swelling of the jaws. *Radiology* 1956; 67:742–745.
10. Bruce KW, Bruwer A, Kennedy RLJ. Familial intraosseous swelling of the jaws ("cherubism"). *Oral Surg Oral Med Oral Pathol* 1953;6: 995–1014.
11. Seward GR, Hankey GT. Cherubism. *Oral Surg Oral Med Oral Pathol* 1957; 10:952–974.
12. Jones WA. Further observations regarding familial multilocular cystic disease of the jaws. *Br J Radiol* 1938; 11:227–241.
13. Bianchi SD, Boccardi A, Mela F, Romagnoli R. The computed tomographic appearances of cherubism. *Skeletal Radiol* 1987; 16:6–10.
14. Mukherjee P, Sinha Roy SK, Mukhopadhyay V. Familial fibrous dysplasia of the jaws: cherubism in two brothers. *Indian Pediatr* 1991; 28:1071–1074.
15. Jaffe HL. Giant-cell reparative granuloma, traumatic bone cyst, and fibrous (fibro-osseous) dysplasia of the jawbones. *Oral Surg* 1953; 6:159–175.
16. Thoma KH. Cherubism and other intraosseous giant-cell lesions. *Oral Surg Oral Med Oral Pathol* 1962; 15 [Suppl 2]:1–4.
17. Jones WA. Cherubism. *Oral Surg Oral Med Oral Pathol* 1965; 20:648–653.
18. Pierce AM, Wilson DF, Goss AN. Inherited craniofacial fibrous dysplasia. *Oral Surg Oral Med Oral Pathol* 1985; 60:403–409.
19. Pierce AM, Sampson WJ, Wilson DF, Goss AN. Fifteen-year follow-up of a family with inherited craniofacial fibrous dysplasia. *J Oral Maxillofac Surg* 1996; 54:780–788.